

## 33 Successful Bone Marrow Transplantation done at Lotus Hospital




Lotus Institute of Hematology, Oncology & Bone Marrow Transplantation

### Dr. Pritesh S. Junagade

MD (Medicine), MRCP (UK)  
MRC Path (Haematology) (UK), CCST (Haemato-Oncology)

Consultant Haematologist, Haemato-Oncologist  
and Bone Marrow Transplant Physician

- Lotus Institute of Haematology and Oncology Nashik
- MGM Hospital, Vashi
- Ex. Honorary Haematologist, Sion Hospital, Mumbai
- Ex. Haematologist-Bombay Hospital and Medical Research Center, Mumbai



For private circulation.

Newsletter Vol 8 Issue 2, June 2017

Dear Friends and colleagues,

By the time this newsletter reaches you greenery would be everywhere and I hope most of you would be outdoors on weekend enjoying mother nature!

With all your support and good wishes we have completed 33 bone marrow transplants at Lotus hospital. I hope you keep your faith in our institute and help us serve better. Sometimes I am not able to talk to you on phone and this sometimes can cause some misconceptions and I sincerely apologize for the same. Today's case is a classic case and I hope you enjoy it.

**Case :** 47 year old female Mrs SS had history of back pain for 3 months before coming to me. She was seen by her family physician and given NSAIDs with relief for 4 days. She developed fever and lower respiratory tract infection and was admitted to a chest physician for 5 days. Hb was 8.6 wbc: 16,200 and platelets were 4.9 lakhs. A chest X ray done then showed lytic lesions. Pneumonia was treated and she was discharged. Back pain continued. She then went to a rheumatologist for evaluation and on MRI was found to have osteoporosis with infiltrative disease and hence was immediately referred to me for further evaluation.

Her main complaint was the pain and weakness and recently developed urinary tract infection. Her Hb was 7.2, wbc: 12,200 and platelets were 3.2 lakhs. She could not walk and was very weak. She had developed compression fracture of D12 vertebra. Bone marrow was done in view of infiltrative disease and Multiple Myeloma was diagnosed as plasma cells in her bone marrow were 55% (normal < 2%). Her Creatinine was 2.6. Serum calcium was normal. Further molecular studies confirmed myeloma with "M" band on serum immunofixation studies.

#### Management :

Treatment was started with Inj. Bortezomib, Dexamethasone and Thalidomide (triple therapy). Her clinical condition improved and without transfusion her Hb improved to 9.2 in 1 month. Her back pain persists but now she can walk with an abdominal belt.

#### Future course :

She will need chemotherapy for 5 months and then she will be taken up for autologous bone marrow transplant.

#### About Multiple Myeloma :

It is a type of cancer which affects **bone marrow** (hence we may get anemia, leucopenia or thrombocytopenia), **kidneys** and the **skeletal system** (leading to lytic bone lesions). It causes reduced immunity leading to recurrent infections. Many patients just present with back pain!



### Learning points :

1. Anemia may have Causes other than nutritional deficiencies.
2. Anemia in elderly population can have malignancy as an underlying cause.
3. Unusual infection should make us think about low immunity.
4. NSAID medication should not be given for a long time
5. X-ray should be reported by qualified radiologist if possible.
6. Timely referral is important in diseases like malignancy.

### Lotus Laboratory news:

We are glad to welcome Dr. Ajit K Junagade (my uncle) and younger brother of Dr. Subhash K Junagade to lotus diagnostics as a pathologist. He is also practicing in Nashik road for many years and will now give his services at Nashik also. We have installed BioMerieux automated microbiology system and a new biochemistry machine recently which help us do almost all the investigations inhouse.

### Lotus Hospital news:

Soon we will be starting state of the art 10 bedded ICU with 2 isolation rooms. Dr. Saket Junagade, Cardiologist will be in charge for the same.



**Dr. Subhash K. Junagade**  
MD (Pathologist)



**Dr. Ajit K. Junagade**  
MD (Pathologist)



**Dr. Pritesh S. Junagade**  
MD (MRCP, CCST.)



**Dr. Saket S. Junagade**  
MD (MRCP, AST.)  
(Cardiologist)

### Blood Collection Centers

**Main Laboratory :-  
Lotus Pathology Laboratory**  
Bhavik Nagar, Opp. Kusumagraj  
Smarak, Vidya Vikas Circle,  
off Gangapur Road, Nashik-422013.  
Tel. No. 912532574967, 912532572002

**Lotus Pathology Laboratory**  
Nadkarni Chambers, First Floor  
Behind Hotel Panchvati, Vakli Vadi,  
Nashik - 422001.  
Cell - 7774079004. Time :- 9am to 7pm


**Lotus Pathology Laboratory**  
Behind Atul Dairy, Trimurti Chowk,  
Cidco, Nashik.  
Cell - 7774077462  
Time :- 8am to 2pm. & 4pm to 8pm

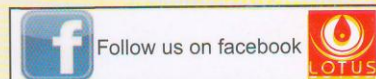
**Lotus Pathology Laboratory**  
Near Ashoknagar Police Chowki,  
Infront of ICICI ATM, Ashoknagar,  
Satpur, Nashik. Cell - 7774073480.  
Time :- 8am to 2pm. & 4pm to 8pm

**Dr. C. J. Badiyani Clinic**  
Kokanipura, Burud Galli, Old  
Nashik.  
Cell - 7774073486  
Time :- 8am to 2pm. & 4pm to 8pm

**Dr. Anil Badiyani Clinic**  
Infront of Panchvati Police Chowki,  
Panchvati Karanja, Nashik.  
Cell - 7774073487.  
Time :- 8am to 2pm. & 4pm to 8pm

**Home Blood Collection No. 7774077261**

 **Charity Wing of Lotus  
Junagade Health Foundation**  
Works for poor patients of cancer & blood diseases.  
Donations are accepted under clause 80G



[www.lotushaematology.com](http://www.lotushaematology.com)

Owner, Printer & Publisher : **Dr. Pritesh S. Junagade**, Bhavik Nagar,  
Opp. Kusumagraj Smarak, Vidya Vikas Circle, Off Gangapur Road,  
Nashik - 400 013. Tel. 0253 - 2574967, Mob. 9860509088,  
For appointments : Mob.: 7774073485  
Email : pritesh.junagade@gmail.com \* www.lotushaematology.com

You can access our previous News Letter on our website.

RNI No. MAHENG / 2011 / 50141

